

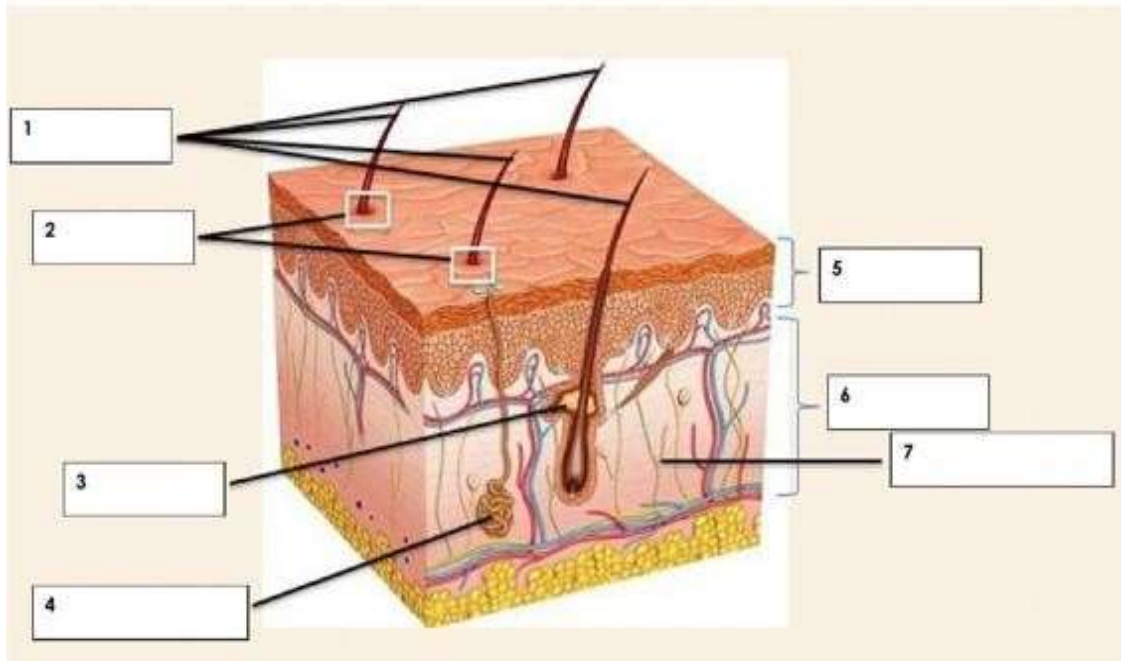
**MINISTRY OF EDUCATION**  
**SECONDARY ENGAGEMENT PROGRAMME**  
**GRADE 8**  
**INTEGRATED SCIENCE**

Week 12

Lesson - Worksheets

Activity 1. Label the parts of the skin

epidermis	fine hairs	sweat gland	nerve endings
dermis	pores	oil ducts	



**Activity 2. Fill in the blank spaces**

1. List the five functions of the integumentary system

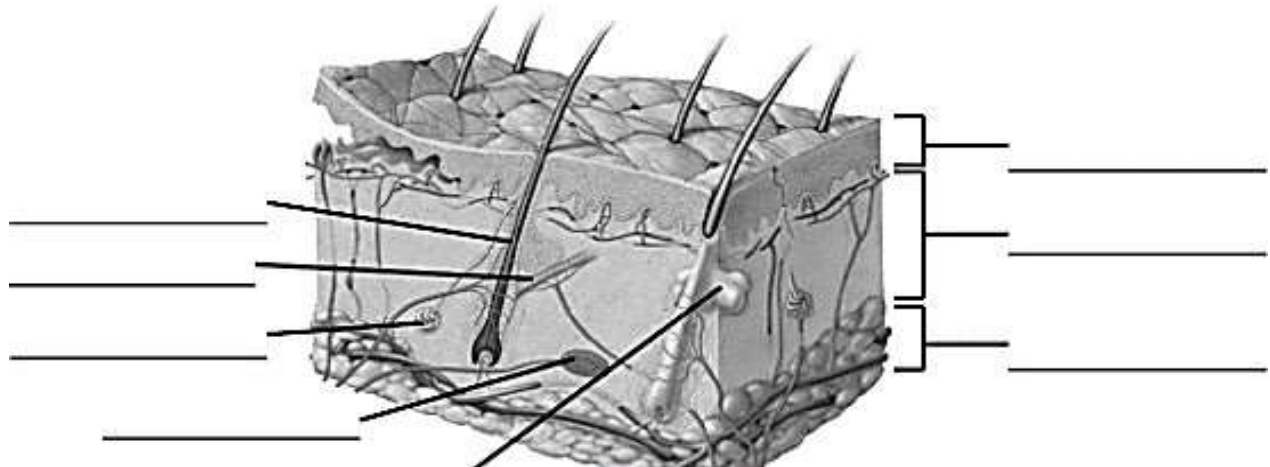
- A.
- B.
- C.
- D.
- E.

2. Match the skin structure to its tissue type  
*(There may be more than one correct answer for each)*


- A. Epidermis \_\_\_\_\_
- B. Dermis \_\_\_\_\_
- C. Subcutaneous \_\_\_\_\_

- I. Simple squamous
- II. Simple cuboidal
- III. Simple columnar
- IV. Stratified squamous
- V. Stratified cuboidal
- VI. Loose Connective
- VII. Adipose
- VIII. Dense Connective

3. Label the following structures on the image



**ACTIVITY 3. Complete the word search below**



- |                      |                 |                    |                  |
|----------------------|-----------------|--------------------|------------------|
| Stratum Corneum      | Stratum lucidum | Stratum granulosum | Stratum spinosum |
| Stratum germinativum | Horny layer     | Transparent layer  | Granular layer   |
| Prickle cell layer   | Basal layer     | Epedermis          | Dermis           |

**MINISTRY OF EDUCATION**  
**SECONDARY ENGAGEMENT PROGRAMME**  
**GRADE 8**  
**INTEGRATED SCIENCE**

**Week 12**

**Lesson - Answers**

**ACTIVITY 1.**

- 1- Fine hairs**
- 2- Pores**
- 3- Oil ducts**
- 4- Sweat glands**
- 5- Epidermis**
- 6- Dermis**
- 7- Nerve endings**

**Activity 2.**

1. List the 5 functions of the integumentary system:
  - A. Body temperature regulation
  - B. Protection
  - C. Cutaneous Sensations
  - D. Excretion and absorption
  - E. Synthesis of Vitamin D
2. Circle the correct answer | True or False | The dermis is superficial to the epidermis.
  - A. Explain your answer:

The epidermis is superficial to the dermis or The dermis is deep to the epidermis

Match the skin structure to its tissue type.

There can be more than one answer. Also, choices may be used once, more than once, or not at all:

3. Epidermis: D
  4. Dermis: F & I
  5. Subcutaneous: F & G
- A. Simple Squamous Epithelial
  - B. Simple Cuboidal Epithelial
  - C. Simple Columnar Epithelial
  - D. Stratified Squamous Epithelial
  - E. Stratified Cuboidal Epithelial
  - F. Areolar Connective Tissue
  - G. Adipose Connective Tissue
  - H. Dense Regular Connective Tissue
  - I. Dense Irregular Connect Tissue

6. Label the following view of the skin:

